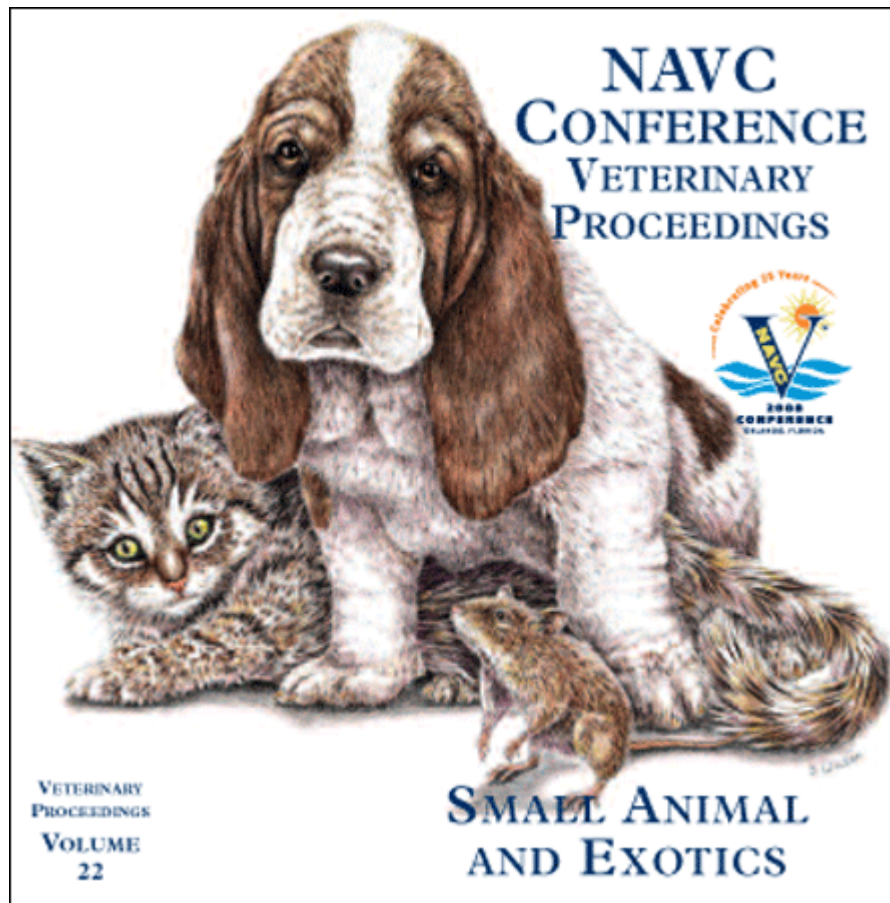


Proceeding of the NAVC
North American Veterinary Conference
Jan. 19-23, 2008, Orlando, Florida



www.tnavc.org

TUMORS OF THE HEART AND HEART BASE

Wallace B. Morrison, DVM, MS, DACVIM
 School of Veterinary Medicine
 Purdue University, West Lafayette, Indiana

Tumors of the heart and heart base are uncommon in dogs and cats. Tumors of the heart can be both primary and metastatic lesions. In humans the frequency of tumors metastatic to the heart is estimated to be 20 to 40 times that of primary heart tumors which themselves occur with a reported incidence of between 0.0017% and 0.19%. The much higher prevalence of metastatic lesions to the heart has also been reported in veterinary literature. However, presumably because of their greater rarity there are more reports of primary cardiac tumors in dogs and cats than there are of metastatic types.

In dogs, hemangiosarcoma is reported to be the most common cardiac tumor. Almost all primary cardiac tumors involve the right side of the heart, especially the right atrium. Other histologic types are reported and include fibroma, fibrosarcoma, rhabdomyoma, rhabdomyosarcoma, myxoma, teratoma, lipofibroma, mesothelioma, granular cell, and others. Tumors of the heart that are located within the lumen of the cardiac chambers (intracavitary) as opposed to the wall or septa are especially uncommon.

Clinical features associated with these tumors are diverse even among tumors of similar size and similar location. Most cardiac tumors are located intrapericardially and cause pericardial effusion and cardiac tamponade that can restrict ventricular filling and result in venous compression and failure behind the heart and poor cardiac output. Some cardiac tumors (most often intracavitary location) do not cause pericardial effusion. Clinical signs in these cases most often are secondary to congestive heart failure or low cardiac output by obstructing blood flow or thromboembolism. Tumors that extensively infiltrate the heart can lead to arrhythmia and/or to poor myocardial contractile function.

Pericardial effusion can be a sequela to tumors of the heart and heart base and is especially common with hemangiosarcoma and chemodectoma. Pericardial centesis is an essential part of the diagnostic evaluation when effusion is present, but it is often unrewarding in establishing a definitive diagnosis. Most tumors of the heart and heart base (lymphoma excepted) do not exfoliate well or often enough to provide markers for a specific tumor type.

A large survey of cardiac tumors in dogs (729,265 medical records queried) found that 46% of all cardiac tumors in dogs were hemangiosarcoma while 5% were aortic body tumors, and 2% were due to lymphoma. A large number of diagnoses in this retrospective multi-institutional study were simply coded as "tumor-heart" (34%) so their true identity was not available for analysis. Presumably some or most of these were metastatic types. Most affected dogs were older, with hemangiosarcoma being reported most commonly in all age ranges affected. Breeds of dogs at higher risk for

developing cardiac tumors were the Saluki, French Bulldog, Irish Water spaniel, Flat-Coated retriever, Golden retriever, Boxer, Afghan hound, English setter, Scottish terrier, Boston terrier, Bulldog, and German Shepherd dog.

Tumors of the heart base arise either from aortic body or carotid body chemoreceptor organs and are collectively termed *chemodectomas* or *heart-base tumors*. Chemoreceptor organs are part of the parasympathetic nervous system and they are sensitive to changes in blood carbon dioxide concentrations, pH, and arterial oxygen tension. They can initiate changes in the depth and rate of respiration, minute volume, heart rate, and arterial blood pressure in response. Although some variation occurs, aortic bodies in dogs are usually located at the base of the heart near the origin of the coronary arteries; dorsal, ventral, and lateral to the aortic arch; between the aorta and the pulmonary artery; and near the root of the right subclavian artery. In cats the left aortic body is located at the base of the left subclavian artery and the right aortic body is located in the angle between the right subclavian and the right common carotid artery. Carotid bodies are located at the bifurcation of the common carotid artery. Most chemodectomas in dogs and cats are nonfunctional but cause clinical signs as a result of mechanical disturbances and space occupation. Tumors of the heart base appear to most common in brachycephalic breeds.

Diagnostic procedures include thoracic and abdominal radiography, electrocardiography, and echocardiography in addition to basic physical examination and clinical laboratory analysis. Echocardiography is especially useful to differentiate heart-base tumors from other cardiac tumors.

Treatment may be merely symptomatic or aggressive. For example, arrhythmias can be suppressed with medication, congestive heart failure can be managed with medication, and effusions can be drained to provide symptomatic relief. In cases of pericardial effusion, pericardectomy can provide relief and reverse heart failure from tamponade. In one study of heart-base masses, dogs that underwent pericardectomy had a mean survival time of 661 days +/- 170 days while dogs that were treated medically had a mean survival of 129 days +/- 51 days.

Surgical resection of the tumor when possible plus pericardectomy and adjuvant chemotherapy (doxorubicin based) was reported in 25 dogs with cardiac hemangiosarcoma and found a median survival of 43 days in dogs with right atrial disease treated by surgery alone, but a median survival of 118 days if the resection was limited to the right atrial appendage. If a doxorubicin-based chemotherapy protocol was given after surgery median survival was 175 days.

REFERENCES

1. MacGregor JM, Faria MLE, Moore AS, et al. Cardiac lymphoma and pericardial effusion in dogs: 12 cases (1994-2004). *J Am Vet Med Assoc.*2005; 227:1449-1453.

Small Animal – Oncology

-
2. Campbell MD, Gelberg HB. Endocardial ossifying myxoma of the right atrium in a cat. *Vet Pathol.*2000; 37:460-462.
 3. Shinohara N, MacGregor JM, Calo A, et al. Presumptive primary cardiac lymphoma in a cat causing pericardial effusion. *J Vet Cardiol.* 2005; 7:65-69.
 4. Tillson DM, Fingland RB, Andrews GA. Chemodectoma in a cat. *J Am Anim Hosp Assoc.* 1994; 30:586-588.
 5. Weisse C, Soares N, Beal MW, et al. Survival times in dogs with right atrial hemangiosarcoma treated by means of surgical resection with or without adjuvant chemotherapy: 23 cases (1986-2000). *J Am Vet Med Assoc.* 2005; 226:575-579.
 6. Ware WA, Hopper DL. Cardiac tumors in dogs: 1982-1995. *J Vet Intern Med.* 1999; 13:95-103.
 7. Vicari ED, Brown DC, Holt DE, et al: Survival times of and prognostic indicators for dogs with heart base masses: 25 cases (1986-1999). *J Am Vet Med Assoc.* 2001; 219:485-487.